

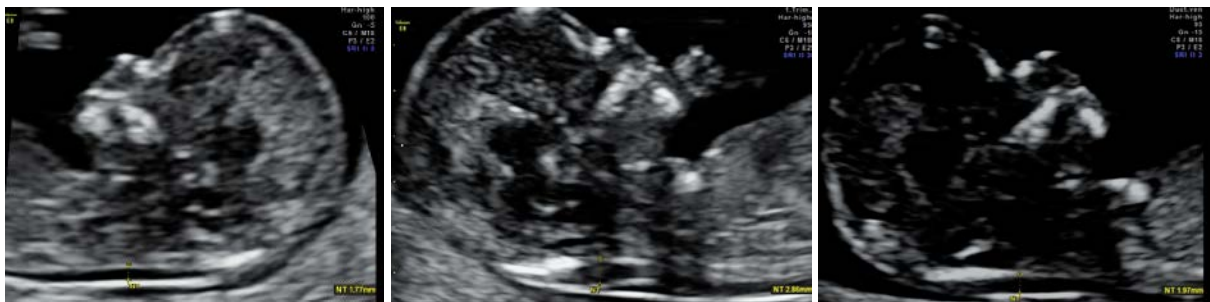Marek Šois, MD
Fetal Ultrasound Screening Center
A.H. Tammsaare tee, Tallinn
Estonia

Dec 18, 2012 FMF ID: 42357

Measurement of nuchal translucency

Dear Marek Šois,

I examined your logbook of 3 images for the following criteria: magnification (head and thorax only), mid-sagittal section of the face, neutral fetal position (no flexion or extension), calliper placement, maximum lucency, and thin nuchal membrane (see table below).



Criteria	Image number		
	1	2	3
Magnification	✓	✓	✓
True mid-sagittal section	✓	✓	✓
Neutral fetal position	✓	✓	✓
Calipers "ON-to-ON"	✓	✓	✓
Maximum lucency	✓	✓	✓
Thin nuchal membrane	✓	✓	✓

Legend: ✓ = pass ✗ = fail -- = not possible to assess

The distribution of your nuchal translucency measurements

You have examined a total of 563 fetuses. The median of your NT distribution is 0.04 mm above what it should be. The scatter of your results is 1.32 times wider than what it should be.

Assuming you screen by NT alone, your detection rate for a false positive rate (FPR) of 3% will be 65.0%, compared to the expected 72.0%. If you screen by NT and biochemistry, the detection rate for a FPR of 3% will be 83.0%, compared to the expected 86.0%.

In screening by NT and biochemistry at a risk cutoff of 1 in 100 the FPR and detection rate should be 2.7% and 84% respectively. On the basis of your distribution the values would be 3.3% and 84.0%.

Your distribution of NT meets the FMF criteria.

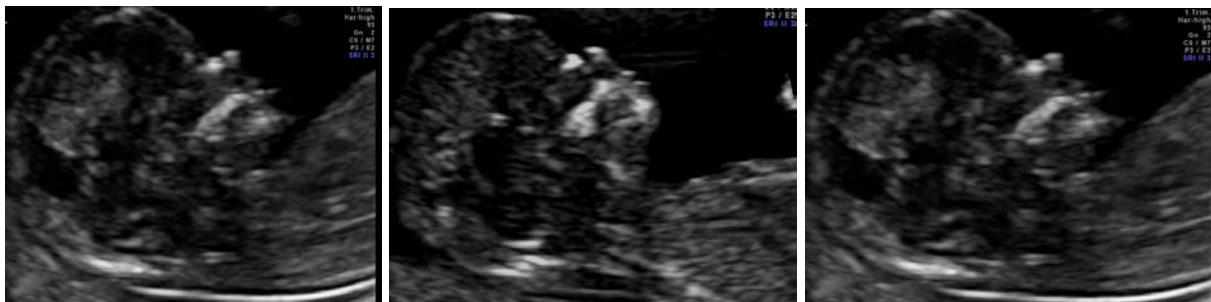Re-audit schedule

Your images are satisfactory and the distribution of your NT measurements was good.

Your name will now be included on the list of certified sonographers with a satisfactory audit on the FMF website. Your license has been extended for one year; your next audit is due in **Nov 18, 2013** and your license expires in **Dec 18, 2013**.

Assessment of the nasal bone

Thank you for submitting. I examined your logbook of 3 images for the following criteria: magnification (head and thorax only), true mid-sagittal section, correct angle between the ultrasound transducer and the nose, and your assessment (see table below).



Criteria	Image number		
	1	2	3
Magnification	✓	✓	✓
Mid-sagittal section	✓	✓	✓
Transducer parallel to the nose	✓	✓	✓
User's assessment	✓	✓	✓

Legend: ✓ = pass ✗ = fail -- = not possible to assess

Your images are satisfactory. Your software license will include the assessment of **nasal bone** in the risk calculation for chromosomal abnormalities and your name will appear on the list of sonographers certified for nasal bone assessment.

Assessment of ductus venosus flow

I examined your logbook of 3 images for the following criteria: magnification , mid-sagittal view , sample volume between 0.5 and 1 mm , angle of insonation angle less than 30 degrees , low filter: 50-70 Hz , high sweep-speed (3-6 waveforms) , and your assessment (see table below).

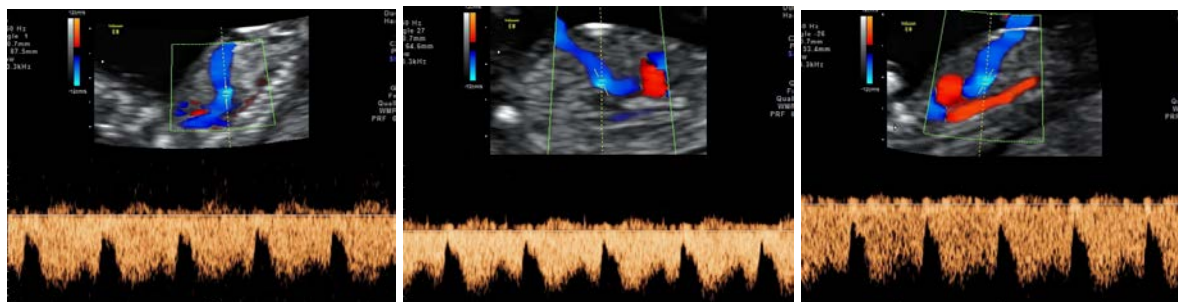


	Image number		
Criteria	1	2	3
Magnification	✓	✓	✓
Mid-sagittal view	✓	✓	✓
Sample volume 0.5-1 mm	✓	✓	✓
Insonation angle less than 30°	✓	✓	✓
Low filter: 50-70 Hz	✓	✓	✓
High sweep-speed (3-6 waveforms)	✓	✓	✓
User's assessment	✓	✓	✓

Legend: ✓ = pass ✗ = fail -- = not possible to assess

Your images are satisfactory. Your software license will include the assessment of **ductus venosus flow** in the risk calculation for chromosomal abnormalities and your name will appear on the list of sonographers certified for ductus venosus assessment.

Assessment of tricuspid flow

I examined your logbook of 3 images for the following criteria: magnification (fetal thorax), apical four chamber view , sample volume size and position, insonation angle < 30°, high sweep-speed (3-6 waveforms) , and your assessment (see table below).

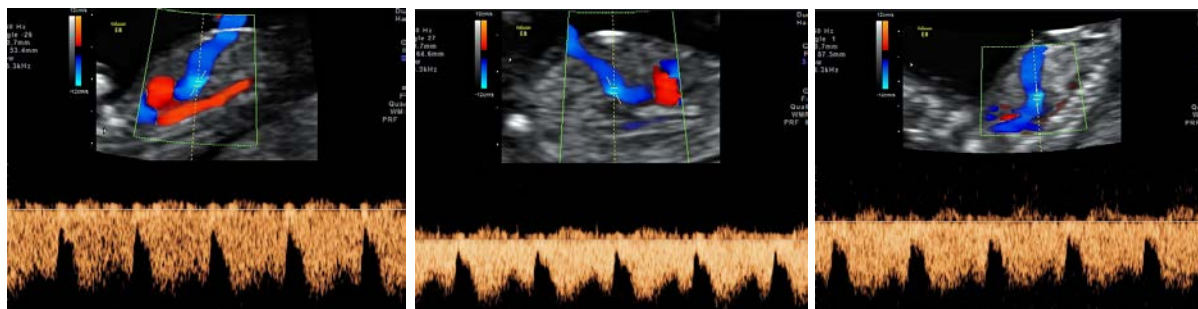


	Image number		
Criteria	1	2	3
Magnification	✓	✓	✓
Apical four chamber view	✓	✓	✓
Sample volume size and position	✓	✓	✓
Insonation angle	✓	✓	✓
High sweep-speed (3-6 waveforms)	✓	✓	✓
User's assessment	✓	✓	✓

Legend: ✓= pass ✗= fail -- = not possible to assess

Your images are satisfactory. Your software license will include the assessment of **tricuspid flow** in the risk calculation for chromosomal abnormalities and your name will appear on the list of sonographers certified for assessment of tricuspid flow.

Measurement of uterine artery PI

I examined your logbook of 3 images for the following criteria: sagittal section , angle of insonation angle less than 30 degrees , velocity more than 60 cm/s , and sample volume 2.0 mm (see table below).

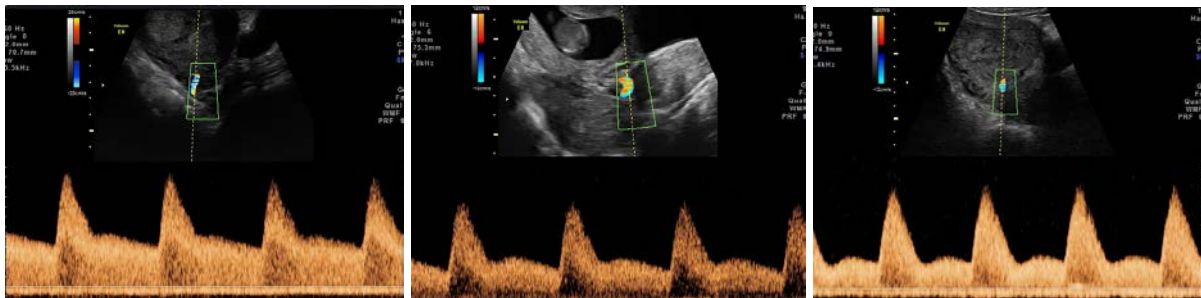


	Image number		
Criteria	1	2	3
Sagittal section	✓	✓	✓
Insonation angle < 30°	✓	✓	✓
Velocity > 60 cm/s	✓	✓	✓
Sample Volume 2.0 mm	✓	✓	✓

Legend: ✓= pass ✗= fail -- = not possible to assess

Your images are satisfactory. Your software license will include the assessment of **uterine artery flow** in the risk calculation for preeclampsia and your name will appear on the list of sonographers certified for assessment of uterine artery flow.

Best wishes,
Olga Torres Khoury